

FRANK H. NETTER, MD

ATLAS  
ANATOMIJE  
ČOVEKA

SEDMO IZDANJE  
ČETVRTO SRPSKO IZDANJE

**Prevodioci i redaktori**

prof. dr sci. med. Milan Milisavljević

prof. dr sci. med. Aleksandar Maliković

Frank H. Netter, MD  
ATLAS ANATOMIJE ČOVEKA

Naslov originala  
ATLAS OF HUMAN ANATOMY, Seventh Edition

Original ISBN: 978-0-323-38322-5  
Standard Edition: 978-0-323-38322-5  
Professional Edition: 978-0-323-55428-2  
International Edition: 978-0-323-38321-8

Izdavač  
DATA STATUS, Beograd  
www.datastatus.rs  
besplatni poziv 0800 300 033

Za informacije  
Predrag Đurković

Urednik edicije  
prof. dr. sci. med. Slavica Đurić

Urednik izdanja  
prof. dr. sci. med. Milan Milosavljević

Prevodilac i redaktor  
prof. dr. sci. med. Milan Milosavljević  
prof. dr. sci. med. Aleksandar Maljković

Lektor  
mi. Yana Marković, za tehnički jezik  
Natalia Paveta

Tehnički urednik  
Vladimir Nedković

Prelom  
Orac studio, Beograd

Stampa  
SP Print, Novi Sad

Tiraž  
2.000 primeraka

Beograd,  
2019.

ISBN: 978-86-7479-640-9

## ELSEVIER

1600 John F. Kennedy Blvd.  
Ste. 1800  
Philadelphia, PA 19103-2899

Copyright © 2019 by Elsevier Inc.  
Previous editions copyright 2014, 2011, 2006, 2001, 1997, 1989

All rights reserved. No part of this publication may be reproduced or transmitted in any form or by any means, electronic or mechanical, including photocopying, recording, or any information storage and retrieval system, without permission in writing from the publisher. Details on how to seek permission, further information about the Publisher's permissions policies and our arrangements with organizations such as the Copyright Clearance Center and the Copyright Licensing Agency can be found at our website: [www.elsevier.com/permissions](http://www.elsevier.com/permissions).

This book and the individual contributions contained in it are protected under copyright by the Publisher (other than as may be noted herein). Permission to use Netter Art figures may be sought through the website [netterimages.com](http://netterimages.com) or by emailing Elsevier's Licensing Department at [H.Licensing@elsevier.com](mailto:H.Licensing@elsevier.com).

This edition of ATLAS OF HUMAN ANATOMY, 7th edition by Frank H. Netter is published by arrangement with Elsevier Inc.

Sva prava zadržana. Sadržaj ove knjige ne sme biti reprodukovani u bilo kom obliku bez pismenog odobrenja izdavača. Zahtev za takvo odobrenje poslati na e-mail: [H.Licensing@elsevier.com](mailto:H.Licensing@elsevier.com).

Ovo izdanje knjige ATLAS ANATOMIJE ČOVEKA, 7. izdanje, autora Franka H. Nettera objavljeno je na osnovu ugovora sa izdavačkom kućom Elsevier Inc.

## UREDNICI KONSULTANTI

**Carlos A. G. Machado, MD**  
Glavni medicinski ilustrator

**John T. Hansen, PhD**

Glavni urednik  
Professor of Neuroscience  
Former Chair of Neurobiology and Anatomy and  
Associate Dean for Admissions  
University of Rochester Medical Center  
Rochester, New York

**Brion Benninger, MD, MSc**

Professor of Medical Innovation, Technology, &  
Research; Professor of Clinical Anatomy  
Executive Director, Chair, Medical Anatomy Center  
Department of Medical Anatomical Sciences  
Faculty College of Dentistry  
Western University of Health Sciences  
Lebanon, Oregon;  
Faculty, Sports Medicine Fellows, Orthopaedic and  
General Surgery Residencies  
Samaritan Health Services, Corvallis, Oregon;  
Faculty, Surgery, Orthopedics & Rehabilitation, and Oral  
Maxillofacial Surgery  
Oregon Health & Science University  
Portland, Oregon

**Jennifer Brueckner-Collins, PhD**

Professor and Vice Chair of Educational Programs  
Department of Anatomical Sciences and Neurobiology  
University of Louisville School of Medicine  
Louisville, Kentucky

**Todd M. Hoagland, PhD**

Professor  
Department of Cell Biology, Neurobiology, and Anatomy  
Medical College of Wisconsin  
Milwaukee, Wisconsin

**R. Shane Tubbs, MS, PA-C, PhD**

Chief Scientific Officer, and Vice President  
Seattle Science Foundation  
Seattle, Washington;  
Professor of Anatomy  
Department of Anatomical Sciences  
St. George's University  
Grenada, West Indies;  
Centre of Anatomy and Human Identification  
Dundee University  
United Kingdom

## UREDNICI PRETHODNIH IZDANJA

*Prvo izdanje*

Sharon Colacino, PhD

*Drugo izdanje*

Arthur F. Dalley II, PhD

*Treće izdanje*

John T. Hansen, PhD

*Četvrto izdanje*

John T. Hansen, PhD  
Jennifer K. Brueckner, PhD  
Stephen W. Carmichael, PhD, DSc  
Thomas R. Gest, PhD  
Noelle A. Granger, PhD  
Anil H. Walji, MD, PhD

*Peto izdanje*

John T. Hansen, PhD  
Brion Benninger, MD, MS  
Jennifer K. Brueckner, PhD  
Stephen W. Carmichael, PhD, DSc  
Noelle A. Granger, PhD  
R. Shane Tubbs, MS, PA-C, PhD

*Šesto izdanje*

John T. Hansen, PhD  
Brion Benninger, MD, MS  
Jennifer Brueckner-Collins, PhD  
Todd M. Hoagland, PhD  
R. Shane Tubbs, MS, PA-C, PhD

# SADRŽAJ

## POGLAVLJE I UVOD • Table 1–7

### Uvod • Table 1–7

- 1 Ravni tela i termini orijentacije
- 2 Površinska anatomija: regioni (pogled spreda, žena)
- 3 Površinska anatomija: regioni (pogled otpozadi, muškarac)
- 4 Velike arterije i tačke palpacije pulsa
- 5 Velike sistemske vene kardiovaskularnog sistema
- 6 Opšta organizacija nervnog sistema
- 7 Pregled limfnog sistema

## POGLAVLJE II CAPUT ET CERVIX (COLLUM) • Table 8–160

### Površinska anatomija • Tabla 8

- 8 Glava i vrat: površinska anatomija

### Glava i vrat: površinski sloj • Table 9–10

- 9 Caput et cervix: innervatio cutis
- 10 Caput: arteriae et venae superficiales

### Kosti i ligamenti • Table 11–30

- 11 Cranium: aspectus anterior
- 12 Lobanja: radiografije
- 13 Cranium: aspectus lateralis
- 14 Lobanja: lateralna radiografija
- 15 Cranium: sectio mediosagittalis
- 16 Calvaria
- 17 Basis cranii externa
- 18 Basis cranii interna
- 19 Basis cranii externa: foramina
- 20 Basis cranii interna: foramina
- 21 Cranium neonati
- 22 Skeleton capitis et cervicis
- 23 Basis cranii externa: aspectus posterior et lateralis
- 24 Mandibula
- 25 Articulatio temporomandibularis
- 26 Vertebrae cervicales: atlas et axis
- 27 Vertebrae cervicales



28	Vertebrae cervicales: articulationes uncovertebrales
29	Ligamenta craniocervicalia externa
30	Ligamenta craniocervicalia interna

#### Vrat • Table 31–41

31	Musculi faciei: aspectus lateralis
32	Musculi cervicis: aspectus anterior
33	Fasciae cervicales
34	Fasciae cervicales
35	Musculi suprahyoidei et musculi infrahyoidei
36	Musculi cervicis: aspectus lateralis
37	Musculi scaleni et musculi prevertebrales
38	Venae superficiales et nervi sensorii cervicis
39	Plexus cervicalis et vasa sanguinea cervicis
40	Plexus cervicalis et arteria subclavia
41	Arteriae carotides

#### Predeo nosa • Table 42–64

42	Nasus
43	Cavitas nasi: paries lateralis
44	Cavitas nasi ossea: paries lateralis
45	Cavitas nasi: septum nasi
46	Cavitas nasi: nervi
47	Cavitas nasi: arteriae
48	Cavitas nasi: nervi
49	Cavitas nasi et sinus maxillaris: sectio transversa
50	Sinus paranasales
51	Sinus paranasales
52	Sinus paranasales: variationes per annos
53	Glandulae salivariae
54	Glandula parotidea et nervus facialis, rami
55	Musculi masticatori et musculi faciei
56	Musculi masticatori
57	Arteria maxillaris
58	Arteria maxillaris
59	Nervus mandibularis (V3)
60	Fossa infratemporalis, aspectus superior
61	Nervus ophthalmicus (V1) et nervus maxillaris (V2)
62	Cavitas nasi: nervi autonomici
63	Nervus maxillaris et arteria maxillaris, rami
64	Basis cranii: arteriae et nervi

#### Predeo usta • Table 65–74

65	Cavitas oris, inspectio
66	Cavitas oris et lingua: innervatio sensoria
67	Palatum durum et palatum molle
68	Cavitas oris: sectiones

69	Cavitas oris: paries inferior
70	Lingua
71	Lingua
72	Isthmus faucium
73	Dentes
74	Dentes

#### Ždrela • Table 75–86

75	Musculi pharyngis: transsectio longitudinalis, aspectus posterior
76	Pharynx: nervi et vasa sanguinea, aspectus posterior
77	Pharynx: sectio mediosagittalis
78	Musculi pharyngis: sectio mediosagittalis
79	Pharynx: transsectio longitudinalis, aspectus posterior
80	unctio pharyngis et oesophagi
81	Musculi pharyngis: aspectus lateralis
82	Nervi capitis et cervicis
83	Arteriae capitis et cervicis
84	Venae capitis et cervicis
85	Vasa lymphatica capitis et cervicis
86	Vasa lymphatica pharyngis et linguae

#### Štitasta žlezda i grkljan • Table 87–93

87	Glandula thyroidea: aspectus anterior
88	Glandula thyroidea et pharynx: aspectus posterior
89	Glandulae parathyroideae
90	Cartilagine laryngis
91	Musculi laryngis
92	Nervi laryngis
93	Musculi laryngis: functio

#### Očna duplja i sadržaj • Table 94–104

94	Palpebrae
95	Apparatus lacrimalis
96	Musculi externi bulbi oculi
97	Nervi orbitae
98	Orbita: dissectio
99	Arteriae et venae orbitae et palpebrarum
100	Bulbus oculi
101	Camerae bulbi, anterior et posterior
102	Lens et zonula ciliaris
103	Vasa sanguinea bulbi oculi
104	Vasa sanguinea bulbi oculi

**Uvo • Table 105–110**

105	Auris: sectio
106	Auris externa et Auris media
107	Cavitas tympani
108	Labyrinthe, osseus et membranaceus
109	Labyrinthe, osseus et membranaceus
110	Labyrinthe, positio

**Moždanice i mozak • Table 111–126**

111	Meninges et Venae diploicae
112	Arteriae durae matris
113	Meninges et Venae superficiales cerebri
114	Sinus durae matris
115	Sinus durae matris
116	Telencephalon (Cerebrum): aspectus lateralis
117	Telencephalon (Cerebrum): aspectus medialis
118	Telencephalon (Cerebrum): aspectus inferior
119	Ventriculi encephali
120	Liquor cerebrospinalis: circulatio
121	Nuclei basales
122	Thalamus
123	Hippocampus et fornix
124	Truncus encephali
125	Truncus encephali et cerebellum
126	Cerebellum

**Lobanjski i vratni nervi • Table 127–146**

127	Nuclei nervi craniales et truncus encephali: schema
128	Nuclei nervi craniales et truncus encephali: schema
129	Nervi craniales: schema
130	Nervus olfactorius (I)
131	Nervus opticus (II)
132	Nervus oculomotorius (III), n. trochlearis (IV) et n. abducens (VI)
133	Nervus trigeminus (V)
134	Nervus facialis (VII)
135	Nervus vestibulocochlearis (VIII)
136	Nervus glossopharyngeus (IX)
137	Nervus vagus (X)
138	Nervus accessorius (XI)
139	Nervus hypoglossus (XII)
140	Plexus cervicalis
141	Nervi autonomici cervicis
142	Nervi autonomici capitis
143	Ganglion ciliare
144	Ganglion pterygopalatinum et ganglion submandibulare
145	Ganglion oticum
146	Organum gustatorum et connexiones neurales

**Vaskularizacija mozga • Table 147–158**

147	Arteriae encephali
148	Arteria carotis interna
149	Arteriae encephali: schema
150	Arteriae encephali: aspectus inferior
151	Circulus arteriosus cerebri (Willis)
152	Arteriae encephali: aspectus anterior et sectio coronalis
153	Arteriae cerebri: aspectus lateralis et medialis
154	Arteriae encephali: fossa cranii posterior
155	Venae encephali: fossa cranii posterior
156	Venae profundae cerebri
157	Venae subependymales cerebri: schema
158	Hypothalamus et hypophysis

**Regionalni MR snimci • Table 159–160**

159	Kranijalni MR snimci (MRA i MRV)
160	Sagitalni i aksijalni MR snimci glave

**Strukture sa velikim kliničkim značajem • Table 2.1–2.3****Mišići u tabelama • Table 2.4–2.8****POGLAVLJE III DORSUM ET MEDULLA SPINALIS • Table 161–186****Površinska anatomija • Tabla 161**

161	Leda: površinska anatomija
-----	----------------------------

**Kosti i ligamenti • Table 162–168**

162	Columna vertebralis
163	Vertebrae thoracicae
164	Vertebrae lumbales
165	Pršljenovi, radiografija i MR snimak
166	Os sacrum et os coccygis
167	Ligamenta columnae vertebralis: regio lumbosacralis
168	Ligamenta columnae vertebralis: regio lumbalis

**Kičmena moždina • Table 169–179**

169	Medulla spinalis in situ
170	Trunci nervorum spinalium et vertebrae, relationes
171	Dermatomata, segmenta sensoria cutis
172	Divisio autonómica, pars sympathica: schema
173	Divisio autonómica, pars parasympathica: schema
174	Meninges et nervi spinales



175	Nervus spinalis et vertebra: sectio transversa
176	Arteriae medullae spinalis: schema
177	Arteriae medullae spinalis
178	Venae medullae spinalis et columnae vertebrales
179	Venae columnae vertebrales: venae vertebrales

### Mišići i nervi • Table 180–184

180	Musculi dorsi: strata superficialia
181	Musculi dorsi: strata intermedia
182	Musculi dorsi: strata profunda
183	Nervi dorsi
184	Regio cervicalis posterior

### Anatomija preseka • Table 185–186

185	Regio lumbalis: sectio transversa
186	Paries thoracis, nervus thoracicus

### Strukture sa velikim kliničkim značajem • Tabla 3.1

### Mišići u tabelama • Table 3.2–3.3

## POGLAVLJE IV THORAX • Table 187–248

### Površinska anatomija • Tabla 187

187	Grudni koš: površinska anatomija
-----	----------------------------------

### Mlečna žlezda • Table 188–191

188	Glandula mammaria
189	Arteriae glandulae mammariae
190	Vasa lymphatica et nodi lymphoidei glandulae mammariae
191	Glandula mammaria: circulatio lymphae

### Zid grudnog koša • Table 192–201

192	Cavea thoracis
193	Costae et articulationes sternocostales
194	Paries anterior thoracis (Pectus)
195	Paries anterior thoracis
196	Pectus, aspectus internus
197	Nervi et arteriae intercostales
198	Paries thoracis: venae
199	Nervus phrenicus
200	Diaphragma: aspectus thoracicus
201	Diaphragma: aspectus abdominalis

### Pluća • Table 202–214

202	Proiectio pulmonum et pleurae: aspectus anterior
203	Proiectio pulmonum et pleurae: aspectus posterior
204	Pulmones in situ: aspectus anterior
205	Pulmones: aspectus medialis
206	Segmenta bronchopulmonalia
207	Segmenta bronchopulmonalia
208	Trachea et bronchi
209	Arbor bronchialis intrapulmonalis: schema
210	Mediastinum, organa
211	Rami et venae bronchiales
212	Vasa lymphatica et nodi lymphoidei pulmonum
213	Thorax, nervi autonomici
214	Arbor bronchialis, innervatio: schema

### Srce • Table 215–233

215	Cor et pericardium in situ
216	Cor: aspectus anterior
217	Srce: radiografije i CT angiogram
218	Basis cordis et facies diaphragmatica
219	Pericardium
220	Mediastinum: sectio transversa
221	Thorax: sectio coronalis
222	Vasa sanguinea cordis
223	Arteriae coronariae
224	Atrium dextrum et ventriculus dexter
225	Atrium sinistrum et ventriculus sinister
226	Valvae et skeleton fibrosum cordis
227	Valvae cordis
228	Atria, ventriculi et septum interventriculare
229	Systema conducente cordis
230	Nervi cordis
231	Innervatio cordis: schema
232	Innervatio arteriarum: schema
233	Circulatio praenatalis et postnatalis

### Sredogrude • Table 234–243

234	Mediastinum: aspectus lateralis dexter
235	Mediastinum: aspectus lateralis sinister
236	Oesophagus in situ
237	Topographia et constrictiones oesophagi
238	Musculi oesophagi
239	Iunctio oesophagi et gastris
240	Arteriae oesophagi
241	Venae oesophagi
242	Vasa lymphatica et nodi lymphoidei mediastini
243	Nervi oesophagi

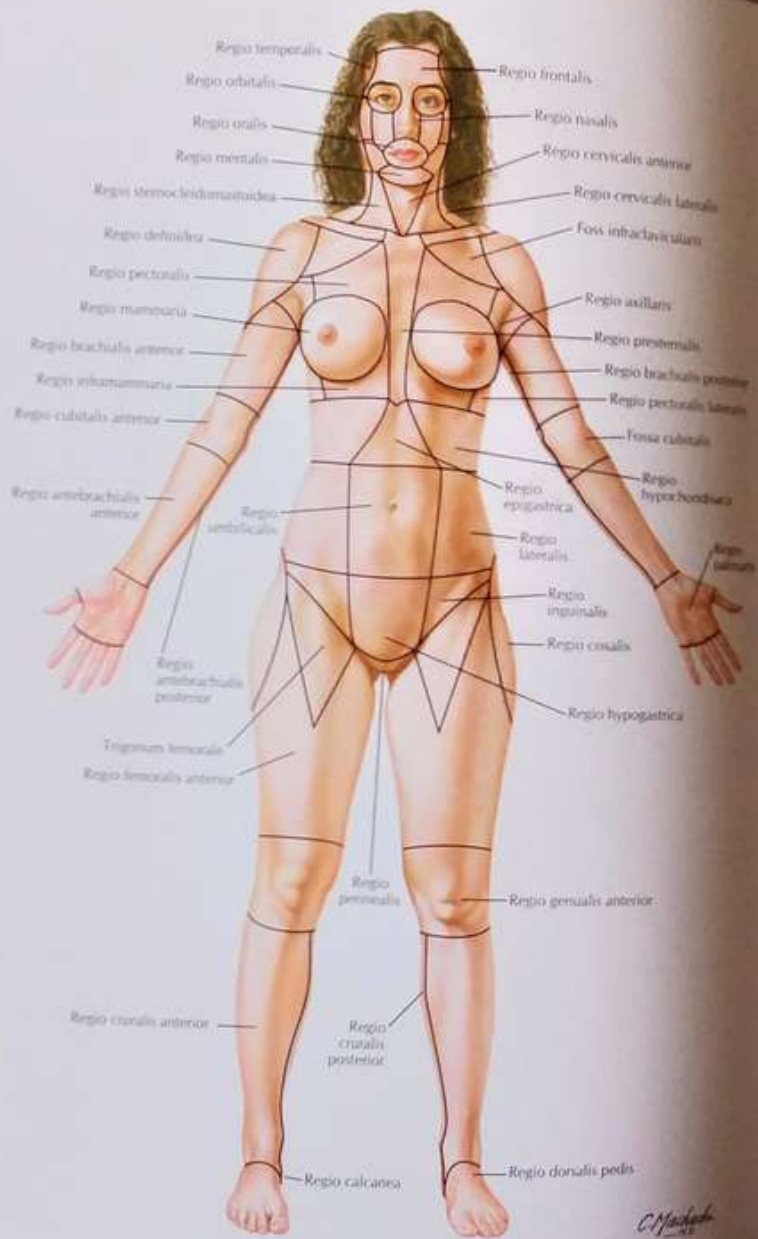


Tabla 2

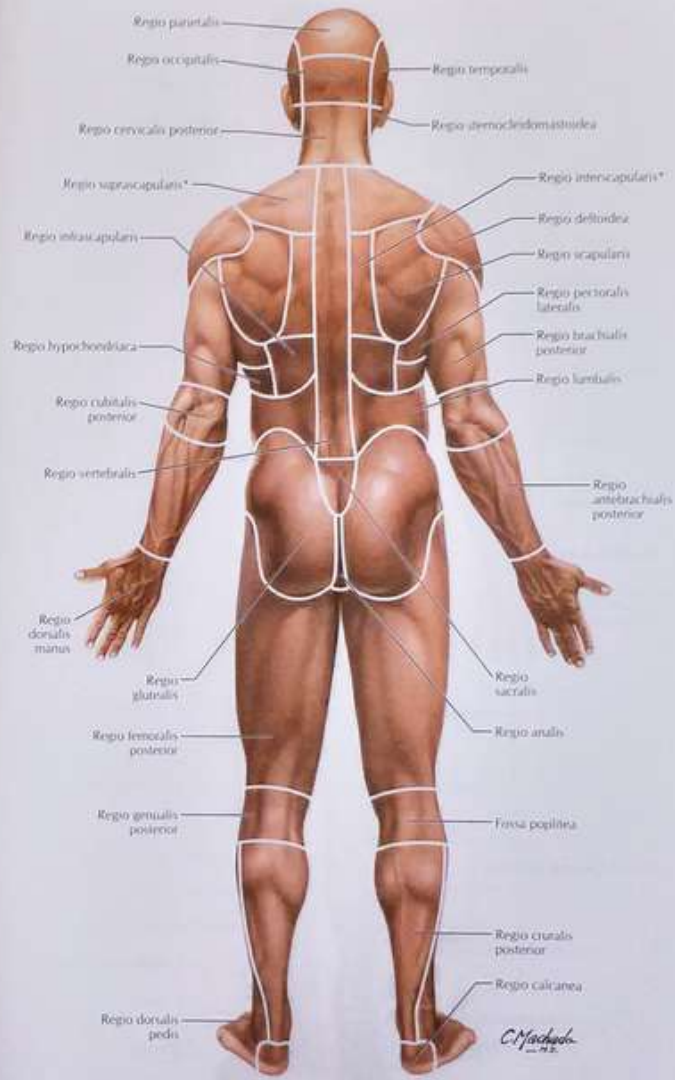


Tabla 3



Vidi takode table 39, 42, 61

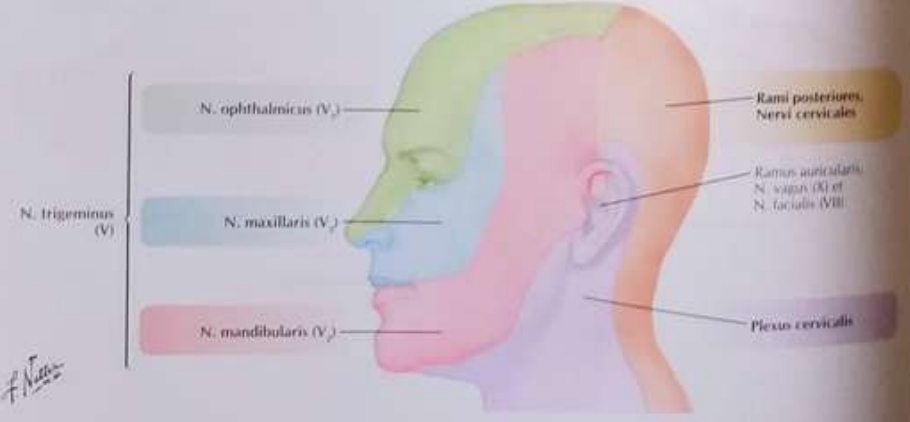
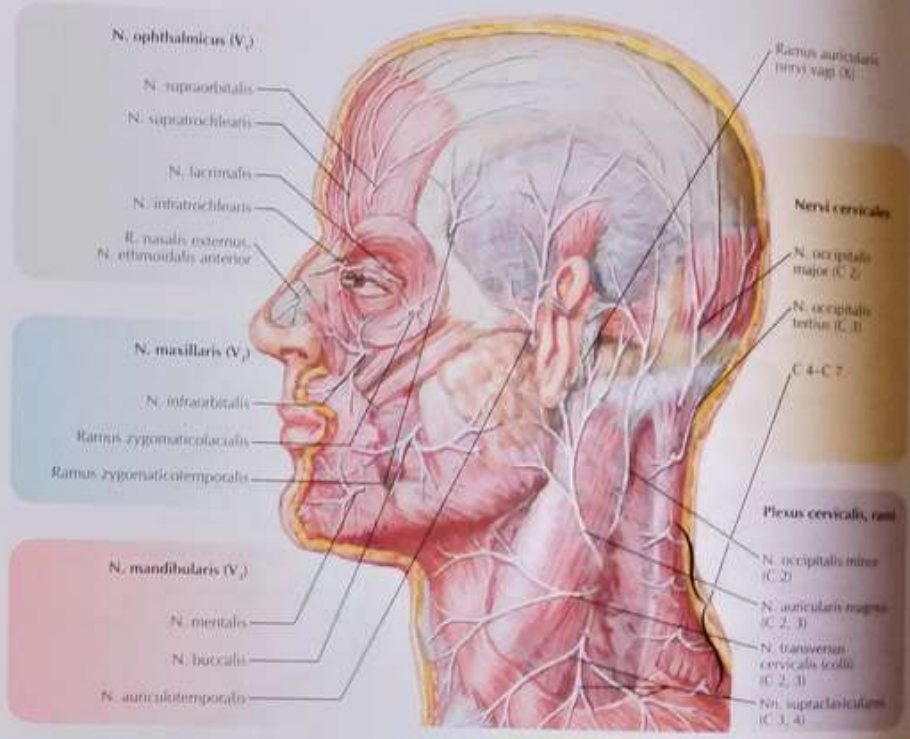
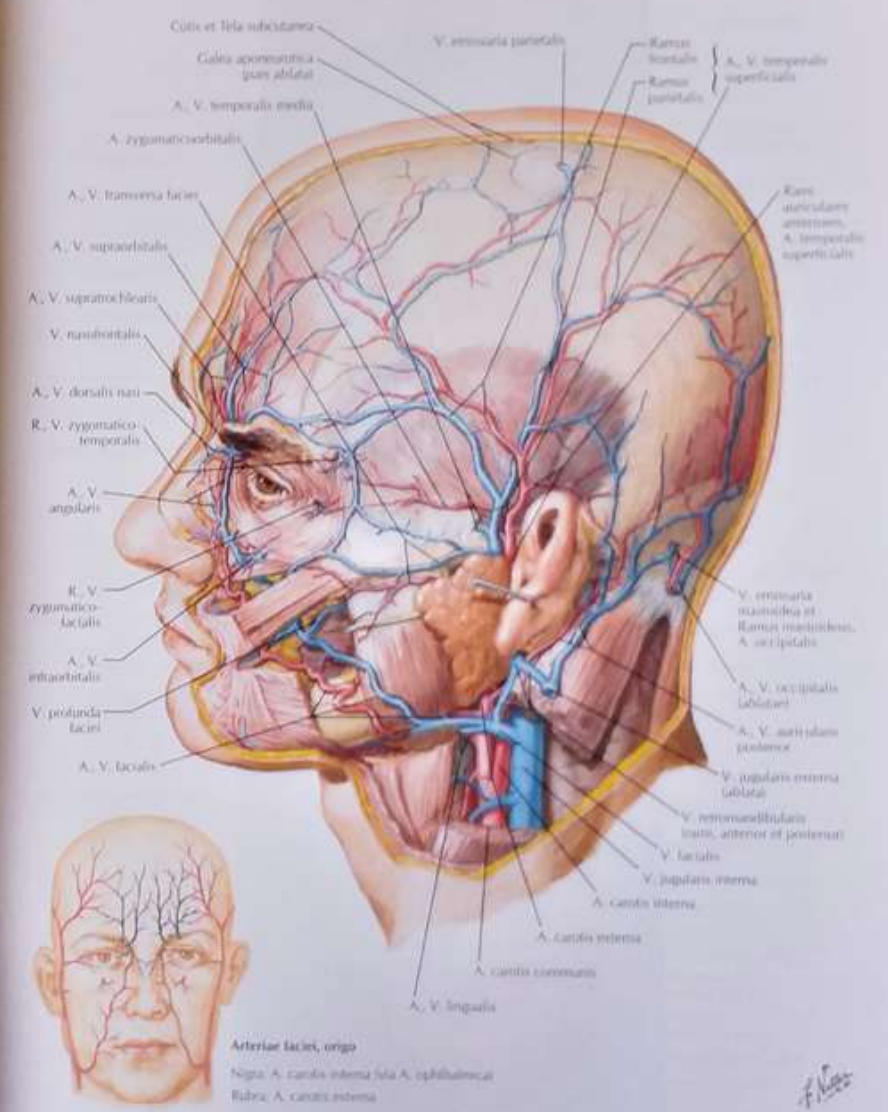


Tabla 9

Glava i vrat: površinski sloj

Vidi takode table 67, 83, 84



Glava i vrat: površinski sloj

Tabla 10



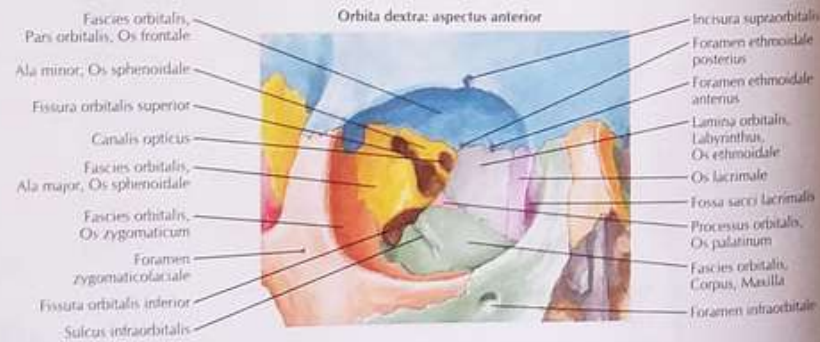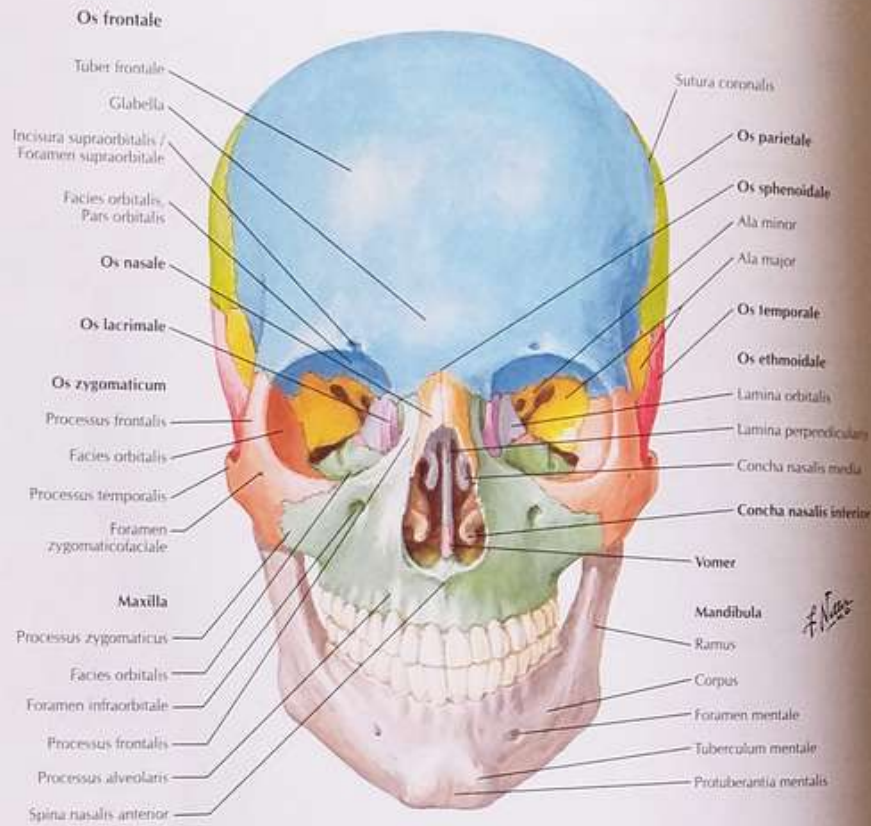
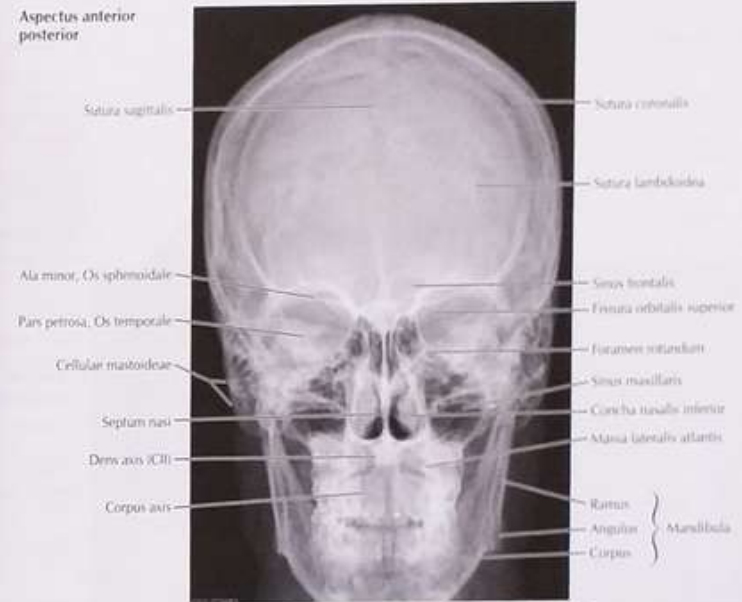


Tabla 11

Aspectus anterior posterior



Aspectus Water; occipitomentalis

